

A Family of Congenital Atransferrinemia

By Nagahide Goya, Sumio Miyazaki, Saburo Kodate, and Bunichi Ushio

An 8-yr-old boy with familial congenital atransferrinemia was studied. He had marked hypochromic anemia but did not respond to administration of iron. The patient responded favorably to parenteral "Eisen-mangel" human serum transferrin. One gram of transferrin was infused intravenously; it disappeared almost completely from the serum within a week. However, the hemoglobin and erythrocytes increased, and there was general improvement in the color and activity of

the patient. After 3-6 mo, his clinical picture had returned to that seen prior to treatment. Thus, it appeared that the hemopoiesis was stimulated by transferrin and that the clinical effectiveness of transferrin was related to the resultant increased red cell production and the duration of the effect to the life-span of the erythrocyte. Neither side effects nor reduction in the effectiveness of transferrin administration was noticed during a year and a half of treatment.

SEVENTEEN YEARS have passed since it was first reported that the basic mechanism of transfer of iron to erythrocytes is mediated by transferrin. There are only three reported cases that were primarily concerned with the clinical aspects of congenital atransferrinemia. We recently studied an additional case in an 8-yr-old boy who had been suffering from a marked hypochromic anemia and who had not responded satisfactorily to iron. The serum transferrin concentration was about half the normal value in his parents and was reduced in an older brother and younger sister. Thus, it appears that this boy represents an interesting case of familial congenital atransferrinemia. He responded favorably to the administration of human serum transferrin, and this is the subject of this report.

CASE STUDIES

The patient (Y. K.) is an 11-yr-old male whose parents were healthy; there was no history of consanguinity. None of the relatives had been known to have anemia or other hematologic disorders, except for a female cousin on the paternal side who died of leukemia.

The patient had been healthy until he became noticeably pale in March 1968, when he was 7 yr old. He was referred to our clinic in July 1968, at which time he had marked pallor. There was a systolic cardiac murmur. The liver edge was 1 cm below the right costal margin, the spleen was not palpable, and there was no lymphadenopathy. No hemorrhagic tendency was detected. The remainder of the history and physical were within normal limits. He was hospitalized on August 3, 1968.

From the Department of Pediatrics, Faculty of Medicine, Kyushu University, Fukuoka City, Japan.

Received August 30, 1971; revised March 25, 1972; accepted April 2, 1972.

Nagahide Goya, M.D.: Associate Professor, Department of Pediatrics, Faculty of Medicine, Kyushu University, Fukuoka City, Japan. Sumio Miyazaki, M.D.: Instructor, Department of Pediatrics, Faculty of Medicine, Kyushu University, Fukuoka City, Japan. Saburo Kodate, M.D.: Research Fellow, Department of Pediatrics, Faculty of Medicine, Kyushu University, Fukuoka City, Japan. Bunichi Ushio, M.D.: Clinical Fellow, Department of Pediatrics, Faculty of Medicine, Kyushu University, Fukuoka City, Japan.

RESULTS

Laboratory Data

The erythrocyte sedimentation rate was 8 mm/1 hr and 24 mm/2 hr. Urinalysis was normal. Frequent tests for fecal parasites and occult blood were negative. The serum LDH was 445 U; SGOT, 26 U; SGPT, 15 U; serum cholesterol, 137 mg/100 ml; and uric acid, 2.7 mg/100 ml. The serum levels of sodium, calcium, chloride, and urea nitrogen were within normal limits. ASLO titer was less than 12 U. CRP was negative. The chest x-ray and the electrocardiogram were normal. The cardiac murmur was assumed to be functional. There was normal gastric acidity.

Hematologic Data and Iron Metabolism

The pertinent hematologic data on the propositus and family members are summarized in Table 1. The erythrocyte count was 3.1×10^6 /cu mm, and the reticulocyte count was 1.3%. The hematocrit was 28.5%. The hemoglobin concentration was 6.4 g/100 ml. The peripheral blood film showed marked hypochromia and aniso- and poikilocytosis. The leukocyte count was 5500 with a normal differential. The platelet count was 1.04×10^5 /cu mm. Hemoglobin electrophoresis was normal; hemoglobin F was 0.3%, and hemoglobin A₂ was within the normal range. The heat stability test gave normal results. The bone marrow showed erythroid hyperplasia. The nucleated cell count of a bone marrow aspirate was 194,500/cu mm. The erythroid series constituted 59.2% of the cells. Proerythroblasts were 3.4%, and sideroblasts were decreased to 9%. There were no abnormal cells. Megakaryocytes were normal.

The patient's serum iron (SI) was 12 μ g/100 ml. Total serum iron-binding capacity (TIBC) was strikingly decreased to 46 μ g/100 ml. Ferrokinetic studies revealed a plasma iron clearance half time (PIDT) of 25 min (normal value, 80–120 min). Red cell iron utilization was 55%, which was significantly lower than the normal value of 85%–95%.

The patient was given 5 μ Ci of ⁵⁹FeCl₃ and 100 mg of vitamin C orally to measure iron absorption. Thirty-nine per cent of the radioactive iron was absorbed, a value significantly higher than the normal of 8%–21%. Ferrokinetic studies and iron absorption were, for the most part, normal in family members (Table 1).

Table 1. Hematologic Data and Iron Metabolism

	Age (yr)	RBC ($\times 10^6$)	Hb (g/dl)	Serum Fe (μ g/dl)	PIDT $\frac{1}{2}$ (min)	RBC Fe- Uptake (%)	Fe Ab- sorp- tion (%)	Serum Trans- ferrin (mg/dl)	¹³¹ - ferrin Trans- ferrin ($\frac{1}{2}$ days)
Grandmother	69	4320	12.8	108	74	85	20	165	—
Father	40	4480	13.6	135	86	87	15	106	7.0
Mother	40	4500	13.1	110	80	90	19	80	7.2
Elder brother	9	4110	12.5	52	75	80	8	14	6.9
Patient	8	3100	6.4	12	25	55	39	Trace	7.0
Younger sister	6	3390	11.8	48	72	92	23	12	7.2
Younger brother	2	4200	13.0	68	90	91	20	135	8.0

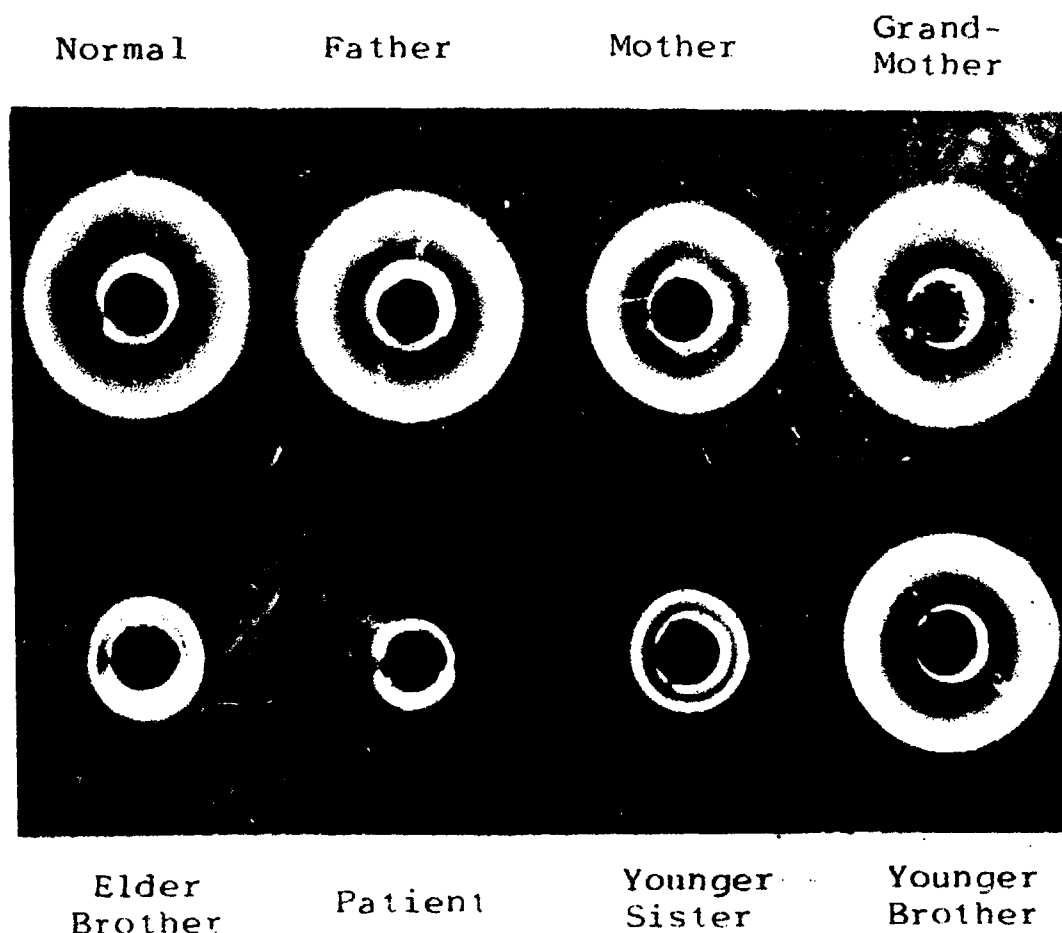


Fig. 1. Serum transferrin levels by single, radial immunodiffusion.

Serum Transferrin

The total serum protein was 7.6 g/100 ml (albumin, 61.5%; α_1 -globulin, 5.0%; α_2 -globulin, 9.2%; β -globulin, 6.7%; γ -globulin, 17.6%). The β -globulin level was low. Since the iron-binding capacity was remarkably low, specific antiserum was used to determine the serum transferrin level by the radial immunodiffusion method (Fig. 1). As shown in Table 1, there was only a trace of transferrin in the serum of the patient (3 mg/100 ml, or less). It was also low in two siblings, 14 and 12 mg/100 ml, respectively, and was almost half the normal value in the parents. The transferrin levels were normal in a younger brother as well as in the grandmother (Table 1). In the siblings who had a marked reduction in transferrin, the serum iron was low, but no anemia was observed.

To study the turnover of circulating transferrin, we used a purified preparation of human transferrin (Behringwerke Laboratory) that showed a single precipitin line on immunoelectrophoresis. The transferrin was labeled with 4 μ Ci/mg 131 I, by the chloramine T method. Free 131 I, was removed by dialysis against 0.01 M phosphate-buffered saline, pH 7.4, and filtration through Sephadex G-25. The transferrin fraction was identified by the radioactivity. Each person was injected intravenously with 3 mg of 131 I-labeled transferrin,

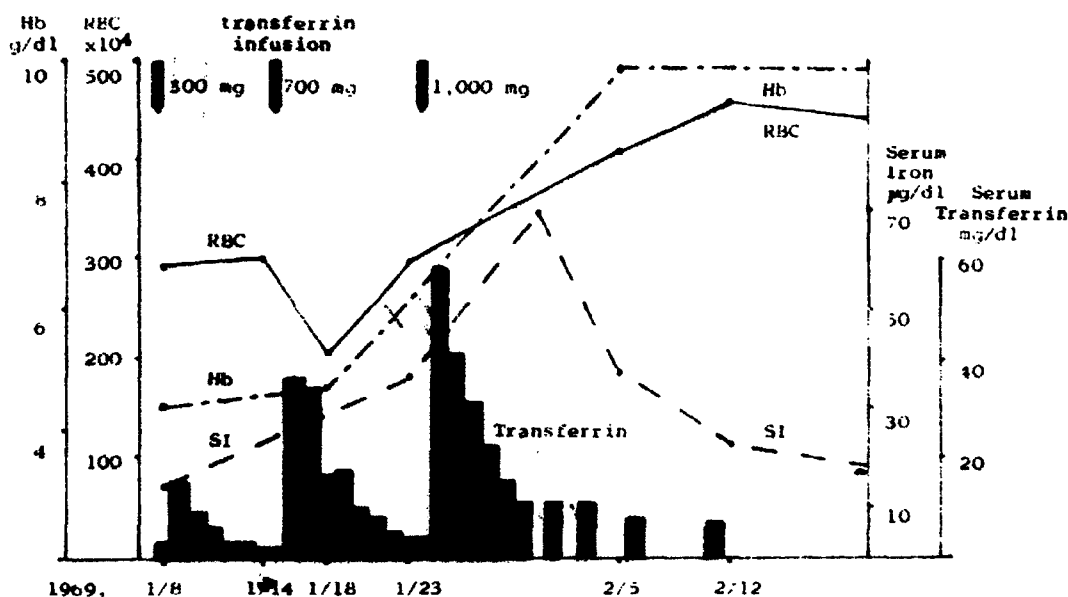


Fig. 2. Hematologic findings after transferrin supplement. 1.

which had been sterilized by Millipore filtration. Blood samples were collected at regular intervals after the injection and the radioactivity were estimated. The $t_{1/2}$ of circulating transferrin was calculated by the method of Awai and Brown.¹ NaI solution was administered daily for 3 days prior to the study and was continued throughout the study in order to block any uptake of ¹³¹I by the thyroid gland. As shown in Table 1, the clearance of labeled transferrin in the patient and members of his family was within the normal range. The $t_{1/2}$ was 7.0 days in the patient and ranged from 6.9 to 8.0 days in the other members of the family. Three control patients were studied. They were a 10-yr-old child with hypoplastic anemia (serum transferrin level: 125 mg/100 ml), a 5-yr-old child with bronchial asthma (180 mg/100 ml), and a 4-yr-old child suffering from the nephrotic syndrome and losing transferrin into the urine (70 mg/100 ml). The $t_{1/2}$ of labeled transferrin in these patients was 7.3, 7.2, and 5.1 days, respectively. No labeled transferrin was detected in urine concentration 100-fold in the propositus or members of his family by the Ouchterlony method with specific antiserum, except for a trace amount in the urine of his younger brother.

Transferrin-supplementing Treatment

A total of 620 ml of blood was transfused during a 4-mo period before it had been established that he had atransferrinemia. This treatment, however, was ineffective. On January 9, 1969, 300 mg of an iron-free human transferrin preparation (kindly supplied by Dr. H. G. Schwick of Behringwerke Laboratory, West Germany) was transfused slowly by the intravenous route (Fig. 2). This 9.8% protein solution revealed several precipitin lines by immunoelectrophoresis, but at least 95% of the material was transferrin, and there was only a trace of iron. The patient had no untoward symptoms, chills, or fever. There was a transient increase in serum transferrin levels to 15 mg/100 ml. One week later, after 700 mg of intravenous transferrin, there was a slight increase

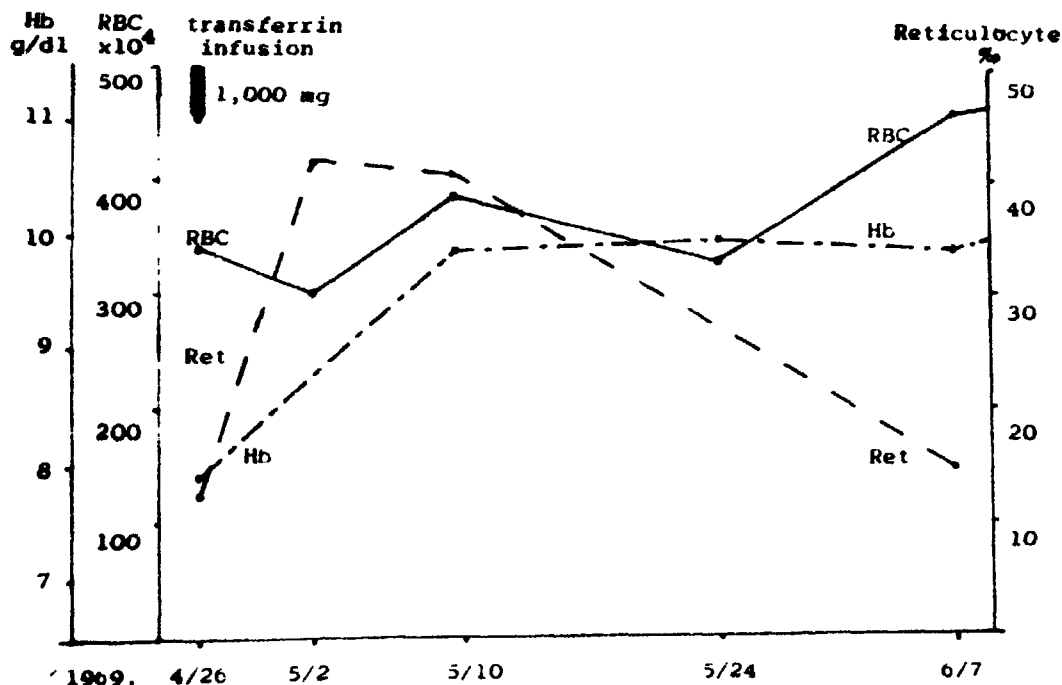


Fig. 3. Hematologic findings after transferrin supplement. 2.

in hemoglobin. After an additional 1000 mg of transferrin 9 days later, the serum transferrin level increased to 56/mg 100 ml soon after the injection and then decreased rapidly. The erythrocyte count increased to 4.5×10^6 by the 18th day, and the hemoglobin content increased to 9.2 g/100 ml. The serum iron level increased to 69 μ g/100 ml 4 days after the injection but subsequently decreased. A bone marrow examination 5 days after the injection showed a nucleated cell count of 296,000/cu mm, with 40.8% erythroid cells (proerythroblast 0.4%) and 20% sideroblasts.

The hemoglobin content remained at 10 g/100 ml. Three months later, however, the erythrocyte count decreased to 3.3×10^6 , and the hemoglobin content decreased to 7.8 g/100 ml. Accordingly, the patient was again treated with 1 g of transferrin intravenously (Fig. 3). The reticulocyte count was 1.2% prior to the injection and increased to 4.0% on the sixth day; the erythrocyte count increased to 3.7×10^6 , and the hemoglobin increased to 9.6 g/100 ml 14 days after the injection. Following this treatment, the hemoglobin content was maintained at a level of 9–10 g/100 ml. Six months after the injection, the erythrocyte count again decreased to 2.0×10^6 and the hemoglobin to 5.6 g/100 ml. The patient was given a third treatment with 1 g of transferrin intravenously and once again responded. Six months later when his erythrocyte count and hemoglobin had fallen to 4.8 g/100 ml, he received further treatment and once again responded.

DISCUSSION

The glycoprotein transferrin (siderophilin) is a β -globulin with a molecular weight of about 90,000; its normal serum level ranges from 200 to 300 mg/100 ml. One molecule of transferrin binds two molecules of trivalent iron, thus playing an important role in the transfer of iron. Acquired hypotransfer-

rinemia is observed in infection (aggregation of transferrin in the inflammatory region), hepatic disorders (decrease in synthesis of transferrin), and malignant tumors.

Only three cases of congenital atransferrinemia have been reported to date. These are summarized in Table 2. In Heilmeyer's case, a diagnosis of severe hypochromic anemia was made 3½ mo after birth.² Treatments with iron preparations, cortisone, and vitamin B₁₂ were ineffective. Blood transfusion was required every 3 mo, and death occurred at the age of 7 yr as a result of severe hemosiderosis. She had growth retardation and repeated infections. The other reported cases^{3,4} also had severe hypochromic anemia, with almost complete absence of serum transferrin, and had symptoms similar to those of Heilmeyer's case.

It is of interest to note that the parents of Heilmeyer's,² Sakata's,⁴ and our present case, and the father of Cáp's case³ had low serum transferrin levels but without anemia. Of three siblings of the patient presented herein, two had low transferrin levels but were not anemic, and the third was normal in both respects. A sibling of Cáp's patient had a mild anemia and a low transferrin level. From these considerations, it is suggested that the inheritance of congenital atransferrinemia is as an autosomal recessive.

In contrast to the patient reported by Heilmeyer, our patient did not have an increased incidence of infection. The serum immunoglobulins were normal in the patient, as well as in his family. It was recently reported that transferrin might possibly be an inactivator of complement C3.⁵ In view of this, it is of interest that the serum complement titers of the present patient and his family were within the normal range.

The degree of iron saturation of transferrin is correlated inversely with the rate of iron absorption.⁶ The rate of iron absorption increases in such disease as iron deficiency anemia where there is an increase in unsaturated iron-binding capacity. The finding that iron absorption was increased in the present case of congenital atransferrinemia suggests that transferrin may not play any essential role in the absorption of iron from the intestine.

When injected intravenously, the transferrin disappeared almost completely

Table 2. Summary of Data Compared With Previously Reported Cases

Authors	Age (yr)	Sex	RBC (× 10 ³)	Hb (g/dl)	Serum Fe (μg/dl)	TIBC (μg/dl)	RBC Fe-uptake (%)	Fe absorption (%)	Serum Transferrin (mg/dl)	¹³¹ I-transferrin (½ days)
Heilmeyer (1961) ²	7	F	4100	9.1	9-14	33	10	30	4.4	—
Cap (1968) ³	11 mo	F	3780	4.8	30	30	—	—	0	—
Sakata (1969) ⁴	10	F	1730	3.2	16	81	53.3	—	39	—
Goya (1971)	8	M	3100 4000- 5500	6.4 12- 17	12 80- 140	46 280- 480	55 85- 95	39 7-21	Trace 200- 300	7.0 6.5- 8.5
Normal			5500	17	140	480	95		300	8.5

from the serum within a week. This time interval is compatible with the known half life of transferrin in the normal circulating blood. Interestingly, hemoglobin and erythrocytes showed an increase that became more and more marked with time. There was general improvement in the complexion and activity of the present patient. Thus, it appeared that hemopoiesis was stimulated by the administration of transferrin. Three to 6 mo later, the child's clinical condition had reverted to that seen prior to treatment with transferrin. This time interval is of interest in view of the life-span of the erythrocyte. In the treatment of agammaglobulinemia with human gamma globulin, the biological function of immunoglobulin (IgG) itself is utilized. Accordingly, the effect of treatment is a function of the disappearance of the administered IgG. On the other hand, the effect of transferrin administered to a patient suffering from atransferrinemia reflects, in part, the stimulation of hemoglobin and erythrocyte production. The duration of this effect is related to the life span of the erythrocyte, rather than to that of the administered transferrin itself.

The advantages of using purified transferrin is that it avoids the administration of iron and large amounts of serum. However, further studies will be necessary to determine whether antibodies to transferrin may eventually develop. During the course of this study it was noteworthy that there were no side effects observed, and the effectiveness of treatment did not decrease with repeated administration, suggesting that antibodies had not developed despite the heterogeneity of the preparation.

ACKNOWLEDGMENT

We wish to thank Dr. K. Nishioka and Dr. M. Torisu of the National Cancer Center, Tokyo, for the estimation of complement, and we express our gratitude to Dr. H. G. Schwick, who made it possible to use a large amount of human transferrin for tentative treatment of the present case.

REFERENCES

1. Awai, M., and Brown, E. B.: Studies of the metabolism of ¹³¹I-labeled human transferrin. *J. Lab. Clin. Med.* 61:363, 1963.
2. Heilmeyer, L., et al. Kongenitale atransferrinämie bei einem sieben Jahre alten kind. *Deutsch. Med. Wschr.* 86:1745, 1961.
3. Cáp, J., Lehotská, V., and Mayerová, A.: Congenital atransferrinemia in an eleven-month-old baby. *Cesk. Pediat.* 23:1020, 1968.
4. Sakata, T.: A case of congenital atransferrinemia. *Shonika Shinryo* 32:1523, 1969.
5. Torisu, M., Sonozaki, H., Shiraishi, S., and Nishioka, K.: Purification of C'3 inactivator from human serum. *Nature (London)* 218:1163, 1968.
6. Taylor, M. R. H., and Gatenby, P. B. B.: Iron absorption in relation to transferrin saturation and other factors. *Brit. J. Haemat.* 12:747, 1966.